Jordan Journal of Applied Science
Natural Science Series

Research Article

Aqueous extract of onion *(Allium cepa)* peel protects brain tissue in ethanol-induced injury by preventing neuronal injury and reducing oxidative stress in BALB/c mice

Helga Bedan Ishaya[1], Martha Orendu Oche Attah[1,2*], Nathan Isaac Dibal[1], Fatimah Buba[3], Hauwa Hajjagana Laminu[4], Ishaku Ayuba Mele[1], Mohammed Musa Usman[3], Martha Shola Peter[1], Sunday Joseph Manye[1], Rukayya Tijjani Adam[1], Abubakar Musa Garba[1]

[1]Department of Human Anatomy, University of Maiduguri, Maiduguri, Nigeria.
[2]Faculty of Medicine, Cyprus International University, Nicosia, Cyprus.
[3]Department of Biochemistry, University of Maiduguri, Maiduguri, Nigeria.
[4]Department of Nutrition and Dietetics, University of Maiduguri, Maiduguri, Nigeria.

ARTICLE INFO

Article history:
Received 24 Sep 2024
Accepted 11 Dec 2024
Published 30 Dec 2024

DOI: 10.35192/jjoas-n.v18i1.2009

***Corresponding author:**

Department of Human Anatomy, University of Maiduguri, Maiduguri, Nigeria.

Email:
mathaorendua@unimaid.edu.ng

Keywords:
Allium cepa
Biomarkers
Cerebellum
Reactive Oxygen Species
Oxidative Stress

ABSTRACT

Background: Oxidative stress is a major factor involved in neuronal injury and brain damage. Medicinal plants like Allium cepa are used to ameliorate oxidative stress because they contain compounds with antioxidant properties. The present research study investigates the mechanism by which Allium cepa ameliorates ethanol-induced brain injury, focusing on the histology of brain tissue and oxidative stress biomarkers to provide a safe and accessible treatment for alcohol-related brain tissue damage and oxidative stress.

Methods: Twenty mice were divided into four equal groups: control (distilled water), negative control (10 mL/kg of 20% alcohol), and treatment groups (50 mg/kg of Allium cepa + 10 mL/kg of 20% alcohol for the low-dose group and 100 mg/kg of Allium cepa + 10 mL/kg of 20% alcohol for the high-dose group). Treatment was administered via the orogastric route for 18 days, after which the mice were sacrificed, and their brains were processed for histopathological analysis and determination of oxidative stress biomarkers.

Results: Treatment with Allium cepa significantly ($p < 0.05$) elevated the activity of catalase, superoxide dismutase, and reduced glutathione, while significantly decreasing malondialdehyde levels in the treated groups. Pyramidal neurons were intact in the treated groups compared to the ethanol-treated groups in the cerebral cortex. Allium cepa also restored and preserved the layers and protected the cells of the cerebellum.

Conclusions/Implications of the Study: By reducing oxidative stress parameters and preserving brain tissue, Allium cepa proves to be a promising, available, and affordable remedy in the investigation of medicinal plants with the potential to alleviate ethanol-induced brain damage.

Introduction

Oxidative stress is defined as a disturbance in the equilibrium between the production of reactive oxygen species (free radicals) and antioxidant defenses (1). Several studies using animal models have reported an increase in reactive oxygen species (ROS) and inflammatory response due to alcohol ingestion and abuse (1-3) Alcohol consumption advances the generation of ROS and/or impedes the body's natural defense mechanisms against these compounds by several processes. Alcohol breakdown results in metabolites that increase cellular ROS, stimulating enzymes that contribute to ROS production, alters the concentration of certain metals in the body which consequently facilitates ROS production and reduces the levels of antioxidants which can ultimately eliminate ROS. These processes accelerate oxidative stress and can leads to cellular injury (2-4). Alcohol-induced oxidative stress emerged as the underlying cause of blood brain barrier (BBB) damage, neuro-inflammation, and neurological diseases (4). However, the role of alcohol-induced oxidative stress in the central nervous system is still largely unknown, especially it effects on the histology of the cerebrum and cerebellum (3,4).
Antioxidants improves the effect of oxidative stress and inflammation caused by alcohol abuse and some natural products which are rich in bioactive compounds are used to re-mediate the toxic effects on the body tissues (4).

Onion (*Allium cepa*) is a common vegetable that is widely cultivated and consumed around the world. Its varied use as a condiment, an ingredient for dishes, and as a medicinal plant is attributed to its therapeutic properties (5). Several documented studies have shown that *Allium cepa* and its bioactive compounds possess several health benefits, such as antioxidant, antimicrobial, neuro-protective, reproductive protective, anti-inflammatory, anti-obesity, anti-diabetic, anticancer, protective to cardiac, vascular, hepatic, renal, respiratory and digestive organs and also has immunomodulatory properties (5). The numerous bioactive constituents found in *Allium cepa* includes organosulfur compounds, phenolic compounds polysaccharides, and saponins (5, 6). *Allium cepa* is found to be a good source of natural antioxidants (6).

The current study was undertaken to investigate the effect of the antioxidants present in *Allium cepa* on the histology of the brain tissue following alcohol-induced tissue damage and determining the oxidative stress biomarkers following ethanol-induced damage with the aim of providing an alternative to reducing oxidative stress related to alcohol abuse. This will provide an accessible and affordable means of treatment in developed and developing countries.

Methods

Chemicals

The chemicals used include hematoxylin, Sodium chloride, ethanol, trichloroacetic acid, formic acid, xylene, sodium carbonate, potassium phosphate, glacial acetic acid and hydrogen peroxide. They are procured from Merck, Germany or Sigma-Aldrich, USA.

Onion Peel and Extraction

Onion peels were procured from Gamboru market, Maiduguri, Nigeria and authenticated at University of Maiduguri, Faculty of Pharmacy and deposited in the herbarium with a reference number

(UMM/FPH/AMA/001). The peels were sun dried, milled and dissolved in ethanol using maceration techniques to produce the ethanol extract as reported in a previous study carried out (7).

Experimental Animals

The experimental study was performed using BALB/c mice of both genders. A total of 20 mice aged 4-5 months weighing 18-21 g were used. The mice were acquired from the National Veterinary Research Institute (NVRI) Vom, Plateau State, Nigeria and housed in the Animal house of the Department of Human Anatomy, Faculty of Basic Medical Sciences, College of Medical Sciences, University of Maiduguri, Borno State for two weeks prior to the start of the experiment to acclimate to the new environment. Five mice were housed in each cage and were accommodated under controlled conditions of humidity (50-60%), temperature of 22°C±3°C, 12 hours light and 12 hours dark in an adequately ventilated room. They were fed with pelleted ECWA (Jos) feed and water *ad libitum.*

Ethical Considerations

This study was conducted in strict accordance and adherence with the recommendations of the National Institutes of Health's Guide for the Care and Use of Laboratory Animals. The research protocol with animal experimentation was approved by the Scientific Ethics Committee of University of Maiduguri (Protocol Number: UM/UGP/22-23/084). All surgery was performed under ketamine hydrochloride and great effort was made to minimize suffering.

Experiment design

Twenty mice were sorted into four groups (5 per cage) and mice in group 1 were given equal volume of distilled water, mice in group 2 were administered 20% ethanol (10 ml/kg). Mice in groups 3 and 4 were administered ethanol extract of *Allium cepa* peel at 50mg/kg and 100mg/kg respectively, followed by 20% ethanol. Doses were determined as a result of the acute toxicity study carried out in a previous studies (8,9). Doses were administered via an orogastric route for a period of 18 days. The mice were euthanized a day after and the brain tissue and cerebellum was carefully harvested. One half of the fresh cerebral and cerebellar cortex of each mouse was preserved in neutral buffer formol, and processed for light microscopy while the other was homogenized in normal saline for oxidative stress studies.

Oxidative stress markers

The homogenized brain was centrifuged and oxidative stress markers; catalase (CAT), superoxide dismutase (SOD), reduced glutathione (GSH), and malondialdehyde (MDA) activities were evaluated from the supernatant according to procedures carried out in previous studies (2,9).

Histological study

Half of each cerebral and cerebellar hemispheres were dehydrated in alcohol, embedded in paraffin, cleared in xylene and sectioned at 5 µm. The sections were stained with Hematoxylin and Eosin (H&E) according to routine histological procedures and micrographs taken at x200 magnification using a microscope (Amscope light microscope (MBJX-ISCOPE, Los Angeles) with a digital camera (M500, X 64, version 3.7) fitted.

Statistical analysis

One-way ANOVA followed by Tukey post-hoc test was carried out using GraphPad Prism 10.0 (San Diego, USA). Statistical significance was considered at $p < .05$ and results were presented as mean ± standard error (SE).

Results

The present research investigated the effect of *Allium cepa* on oxidative stress parameters in ethanol induced cerebral and cerebellar damage and to the histology of these tissues. Administration of *Allium cepa* caused a significant ($p<0.05$) increase in CAT activity at a concentration of 100mg/kg when compared to the control group. CAT activity was significantly ($p<0.05$) decreased in the group that was administered 20% ethanol (which served as the negative control group) when compared to the *Allium cepa* treated mice that received 100mg/kg of the extract and the control group. The increase was not significant in the group that was administered 50mg/kg of *Allium cepa* when compared with the group that received 20% ethanol, Figure 1.

There was a significant ($p<0.05$) increase in SOD activity in the mice that were administered 50mg/kg and 100mg/kg of *Allium cepa* when compared to the control group. The increase was also significant when compared with SOD activity in the ethanol treated group, Figure 1.

Reduced glutathione (GSH) activity was also elevated significantly ($p<0.05$) in the group that was administered with 100mg/kg of extract when compared to the control and ethanol treated groups. At a concentration of 50mg/kg of *Allium cepa*, the increase in activity was not significant when compared to the control group but significant when compared with the ethanol-treated mice, Figure 1.

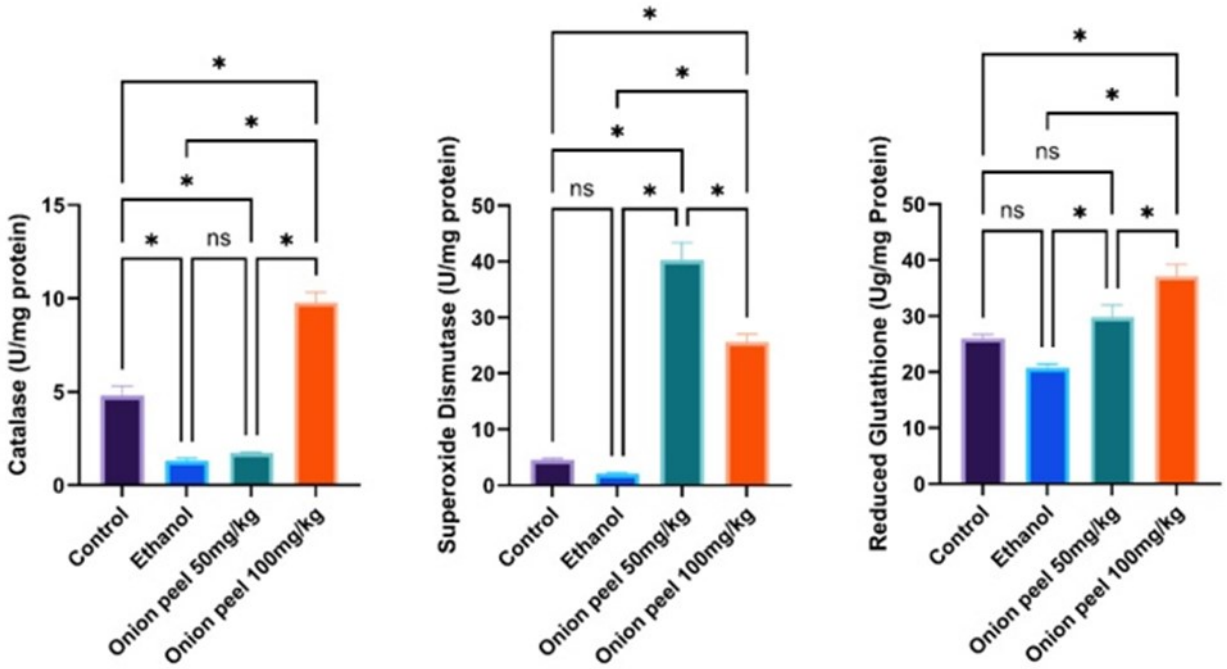

Figure 1. showing the effect of *Allium cepa* peel extract on catalase, superoxide dismutase and reduced glutathione activity in all groups (* - Statistical significance considered at $p< .05$. All value presented as mean ± standard error (SE), ns – not significant, U/mg– unit/milligram).

Malondialdehyde (MDA) concentration was significantly ($p<0.05$) elevated in the ethanol treated mice when compared to the control group and *Allium cepa* administered mice at a concentration of 50mg/kg and 100mg/kg. Administration of the extract non-significantly decreased MDA activity in the treated groups at a concentration of 50mg/kg and significantly decreased ($p<0.05$) in the group that received 100mg/kg compared with the ethanol administered mice, Figure 2.

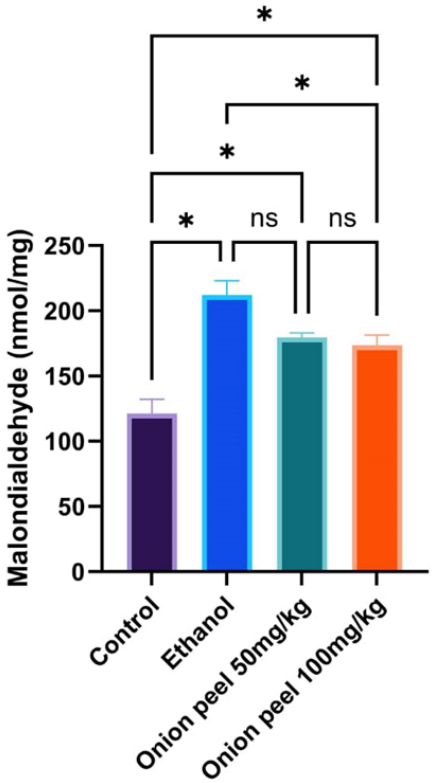

Figure 2. showing the effect of *Allium cepa* peel extract on maolondialdehyde concentration in all groups (* - Statistical significance considered at p< .05. All value presented as mean ± standard error (SE), ns – not significant, nmol/mg – nanomol/milligram).

Histological analysis of the cerebral cortex showed the neuronal cells with their rounded basophilic nuclei easily identifiable. Numerous neuroglia were found distributed along with the pyramidal neurons in the control and *Allium cepa* treated groups. In the ethanol treated group, there was neuronal degeneration which was identified by the numerous vacuoles in the cerebral cortex, with some perinenural oedema. Neuroglia were also very few in this group. Treatment with *Allium cepa* preserved the neurons and neuroglia at a concentration of 50mg/kg and 100mg/kg, Figure 3.

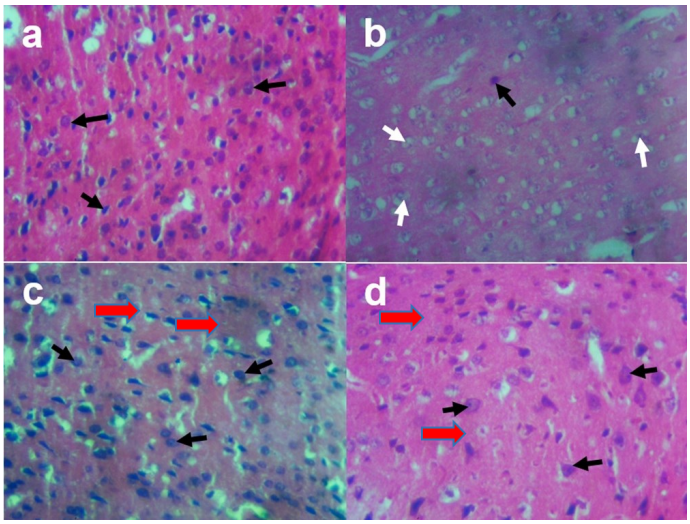

Figure 3. a-d shows the photo micrograph of the cerebral cortex in all groups showing the pyramidal neurons (black arrow) and neuroglia (red arrow) which are abundant in the control group (3a) and treated groups (3c,d) but sparse in the ethanol-treated group (3b). Note that neuronal degeneration (white arrow) with some perineuronal oedema were observed in the ethanol group with very few pyramidal cells and neuroglia (Hx and E X200).

The cerebellum in the control group presented three layers; the granular layer was densely packed with granular cells, the Purkinje cell layer which separated the granular layer from the molecular layer contained several Purkinje cells which were distinguished by their large and acidophilic cytoplasm. The molecular layer was also densely packed with several neural cells. In the ethanol treated group, granular layer was sparse, when compared to the control group, fewer Purkinje cells were observed and the molecular layer contained fewer cells as well. Treatment with *Allium cepa* showed a compact and cellular granular layer in both groups and several Purkinje cells in the Purkinje layer as well as a cellular molecular layer, Figure 4.

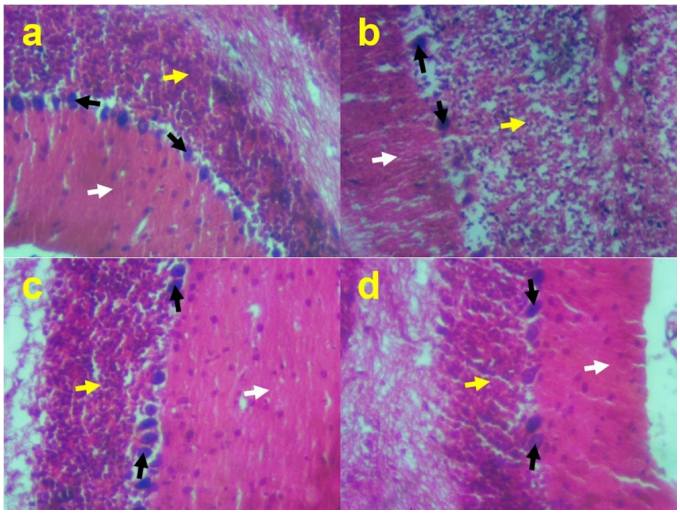

Figure 4. a-d showing the cerebellar layers in all groups. The granular layer which had fewer granular cells in the ethanol treated group. Note that the Purkinje cells (black arrows) were also sparse in the same group. The neurons in the molecular layer (white arrows) were also sparse in group 4b when compared to the *Allium cepa* treated groups (4c and d) H x E X 200

Discussion

Alcohol abuse has been linked with several economic, physiologic and clinical consequences. These consequences may be short term for example accidents and unwanted pregnancies or they may be long term which includes damage to organs like the liver, spleen, kidney, bone tissue, gastrointestinal tract and especially the brain tissue, causing detrimental neuro-biological disturbances (10). Onion (*Allium cepa*) is one of the promising natural resource to develop medicinal alternatives (5).

Allium cepa in the present study significantly elevated CAT, SOD and GSH activity and also significantly reduced MDA levels when compared to the negative control group. Many studies carried out support the results that were obtained in the present study by highlighting the antioxidant properties of *Allium cepa*. In one of such studies, *Allium cepa* was found to up regulate oxidative stress enzymes Haem oxygenase 1 (HO-1), NAD(P):quinone acceptor oxidoreductase1 (NQO1) and CAT (11). In yet another study,(12) reported that *Allium cepa* enhanced the activity of CAT, SOD and GPx enzymes in erythrocytes and liver tissue. Nwonuma *et. al.,* (13) reported that *Allium cepa* protected the liver and kidney against oxidative damage; reducing MDA levels and restoring the architecture of liver and kidney cells. Omar *et. al.,*(14) also reported that *Allium cepa* enhanced CAT, SOD, GSH and thiol levels. Law *et. al.,* (15) reported that *Allium cepa* reduced total free radicals, superoxide anions levels and elevated glutathione content and total antioxidant capacity in healthy African catfish. *Allium cepa* has an antioxidant effect because of its sulfur-containing compounds, such as onionin A and cysteine sulfoxide, as well as the phenolic compounds, such as quercetin and quercetin glucosides which are essential bioactive constituents in onion and contribute to its multiple health functions which includes antioxidant, antimicrobial, anti-inflammatory, and immunomodulatory properties (5). Treatment with ethanol caused neuronal degeneration which was characterized by numerous vacuoles in the cerebral cortex, perinenural oedema and few neuroglia. Treatment with *Allium cepa* preserved the histology of the cerebral cortex and cerebellar tissue and cells were preserved.

The result observed from this study tallies with research work carried out by several researchers on various components of *Allium cepa*. Its leaf extract was found to have neuroprotective function which is attributed to its anti-neuroinflammatory function as reported by (11, 16). Tamtaji *et. al.,* (17) reported that *Allium cepa* improved learning and memory impairments in streptozotocin-induced diabetic rats. Khan *et. al.,* (18) also reported that *Allium cepa* ameliorated diabetes-induced and chronic constriction injury-induced neuropathic pain in rats with neuropathic pain. Kumar *et. al.,* (19) reported that *Allium cepa* played an important role in ameliorating retinal damage by regulating the expression of neurotrophic factors. Singh *et. al.,* (20) proposed that *Allium cepa* improved memory and sensorimotor factors in cerebral injury in mice with cerebral ischemia-reperfusion injury. Hyun *et. al.,* (21) investigated the potential effect of *Allium cepa* extract on brain-ischemia induced edema and demonstrated that the extract prevented brain edema, blood brain barrier (BBB) hyper permeability, tight junction protein disruption, possibly through its antioxidant effects in the middle cerebral artery occlusion model mice. In an investigation carried out by Hegazy *et. al.,* (22) determined the effect of *Allium cepa* and garlic extract on the brain tissue of Alzheimer's disease model mice and reported that administration of the extract had a protective effect on the brain tissue by decreasing histopathological lesions and inhibited ROS generation in brain tissue and this effect could be attributed to its high flavonoid content which improved antioxidant capacity and gene expression patterns. The researchers concluded that the presence and of higher activity of free radical scavenging of azino-bis (3-ethylbenzothiazoline-6-sulphonic acid (ABTS) and antioxidant ferric reducing antioxidant power (FRAP) levels present in the garlic root extraction could be possibly responsible for its protective effect against neurodegenerative damage in Alzheimer-induced brain damage. (23) demonstrated that repeated administration of onion extract for 15 days prior to ischemic surgery protected pyramidal neurons of the hippocampus from ischemic damage and activated astrocytes and microglia further proving its neuroprotective property.

In the present study, the effect of ethanolic extract of *Allium cepa* was investigated to determine its effect on the histology of the cerebral cortex and cerebellum and oxidative stress parameters.

This extract was chosen as methanolic extract has been used in a previous study to determine the effect of *Allium cepa* on the oxidative stress parameters in diabetic rats. In that study, *Allium cepa* caused a loss in body weight, decreased plasma glucose level, and significantly ameliorated the hyperalgesia, TBARS, serum nitrite and GSH levels in diabetic mice (24).

Conclusions

The use of medicinal herbs is popular among the public and scientific community in both developing and developed countries because it is cost-effective, easily accessible, and with relatively lesser adverse effects. *Allium cepa* is one of the plants that has varied medical application and in the current research was found to preserve the histology of the brain tissue and significantly decreased oxidative stress biomarkers in ethanol treated groups.

Supplementary Material

List of abbreviations

CAT- catalase, SOD- Superoxide dismutase, GSH – reduced glutathione, MDA- malondialdehyde, BBB- Blood Brain Barrier, FRAP - ferric reducing antioxidant power, NQO 1 - NAD (P):quinone acceptor oxidoreductase1, HO-1 - Haem oxygenase 1 (HO-1).

Availability of Data and Materials

Data supporting the findings are available on request from the Authors

Competing Interests

The Authors have no conflict of interest to declare

Funding

The Authors have no financial information to declare

Authors Contributions

Conception: HIB, MOOA, NID, FB, HHL, IAM, MMU, MSP, SJM and RTA **Design:** HIB, MOOA, NID, FB, HHL **Data Collection:** IAM, MMU, MSP, SJM and RTA **Data Analysis:** HIB, MOOA, NID, FB, HHL **Data Interpretation:** HIB, MOOA, NID, FB, HHL, **Writing:** HIB, MOOA, NID, FB, HHL, IAM, MMU, MSP, SJM and RTA **Manuscript Approval:** HIB, MOOA, NID, FB, HHL, IAM, MMU, MSP, SJM and RTA **Funding:** IAM, MMU, MSP, SJM and RTA

Acknowledgements

The Authors will like to acknowledge the support of Dr Musa Samaila Chiroma and Dr Joseph Vandi Zirahei for their academic support.The Authors acknowledge the staff of the Gross Anatomy Laboratory and Biochemistry Laboratory, University of Maiduguri for their support during the course of the research work.

References

1. Ge N, Liang H, Zhao Y, Liu Y, Gong A, Zhang W. Aplysin protects against alcohol-induced liver injury via alleviating oxidative damage and modulating endogenous apoptosisrelated genes expression in rats. J Food Sci. 2018;83(10):2612–21. doi:10.1111/1750-3841.14320
2. Attah MO, Jacks TW, Garba SH, Balogun SU . Leptadenia hastata Leaf Extract ameliorates oxidative stress and serum biochemical parameters in Streptozotocin-Induced diabetes in Wistar rats, J Diabetes Metab Disord 2022;21(21):1273-1381 doi:10.1007/s40200-022-01017-z
3. Tsermpini EE, Plemenitaš Ilješ A, Dolžan V. Alcohol-Induced Oxidative Stress and the Role of Antioxidants in Alcohol Use Disorder: A Systematic Review. Antioxidants (Basel). 2022 Jul 15;11(7):1374. doi: 10.3390/antiox11071374 PMID: 35883865; PMCID: PMC9311529.
4. Wang X, Dong K, Ma Y, Jin Q, Yin S, Wang S. Hepatoprotective effects of chamazulene against alcohol-induced liver damage by alleviation of oxidative stress in rat models. Open Life Sci. 2020 Apr 20;15(1):251-258. doi: 10.1515/biol-2020-0026. PMID: 33817213; PMCID: PMC7874619.
5. Zhao XX, Lin FJ, Li H, Li HB, Wu DT, Geng F, Ma W, Wang Y, Miao BH, Gan RY. Recent Advances in Bioactive Compounds, Health Functions, and Safety Concerns of Onion (Allium cepa L.). Front Nutr. 2021 Jul 22;8:669805. doi: 10.3389/fnut.2021.669805. PMID: 34368207; PMCID: PMC8339303.
6. Sidhu JS, Ali M, Al-Rashdan A, Ahmed N. Onion (Allium cepa L.) is potentially a good source of important antioxidants. J Food Sci Technol. 2019 Apr;56(4):1811-1819. doi: 10.1007/s13197-019-03625-9. Epub 2019 Feb 13. PMID: 30996417; PMCID: PMC6443770.
7. Dibal NI, Garba SH, Jacks TW. Acute Toxicity of Quercetin From Onion Skin in Mice. Pharm Biomed. Res. 2020;6(4):269-276. doi:10.18502/PBR.V6I4.5113 Corpus ID: 231773067
8. Dutta S, Sengupta P. Men and mice: Relating their ages. Life Sci. 2016 May 1;152:244-8. doi: 10.1016/j.lfs.2015.10.025. Epub 2015 Oct 24. PMID: 26596563.
9. Dibal NI, Garba SH, Jacks TW. Onion Peel Quercetin Attenuates Ethanol-Induced Liver Injury in Mice by Preventing Oxidative Stress and Steatosis. Biomed Res Ther, 2022; 9(6), 5101-5111. doi:10.15419/bmrat.v9i6.745
10. Arumugam MK, Chava S, Perumal SK, Paal MC, Rasineni K, Ganesan M, Donohue TM Jr, Osna NA, Kharbanda KK. Acute ethanol-induced liver injury is prevented by betaine administration. Front Physiol. 2022 Oct 4;13:940148. doi: 10.3389/fphys.2022.940148. PMID: 36267591; PMCID: PMC9577233.
11. Jakaria M, Azam S, Cho DY, Haque ME, Kim IS, Choi DK. The Methanol Extract of Allium cepa L. Protects Inflammatory Markers in LPS-Induced BV-2 Microglial Cells and Upregulates the Antiapoptotic Gene and Antioxidant Enzymes in N27-A Cells. Antioxidants (Basel). 2019 Sep 1;8(9):348. doi: 10.3390/antiox8090348. PMID: 31480531; PMCID: PMC6770444.
12. Colina-Coca C, Gonzalez-Pena D, de Ancos B, Sanchez-Moreno C. Dietary onion ameliorates antioxidant defence, inflammatory response, and cardiovascular risk biomarkers in hypercholesterolemic Wistar rats. J Funct Foods, 2017;36:300–9. doi:10.1016/j.jff.2017.07.014

13. Nwonuma CO, Osemwegie OO, Alejolowo OO, Irokanulo EO, Olaniran AF, Fadugba DO, Opaleke DO, Ojo OA. Antioxidant and the ameliorating effect of Allium cepa (Onion) fortified feed against potassium bromate induced oxidative damage in Wistar rats. Toxicol Rep. 2021 Mar 31;8:759-766. doi: 10.1016/j.toxrep.2021.03.029. PMID: 33854953; PMCID: PMC8027521.
14. Omar AE, Al-Khalaifah HS, Mohamed WAM, Gharib HSA, Osman A, Al-Gabri NA, Amer SA. Effects of Phenolic-Rich Onion (Allium cepa L.) Extract on the Growth Performance, Behavior, Intestinal Histology, Amino Acid Digestibility, Antioxidant Activity, and the Immune Status of Broiler Chickens. Front Vet Sci. 2020 Nov 12;7:582612. doi: 10.3389/fvets.2020.582612. PMID: 33282930; PMCID: PMC7689185.
15. Law YY, Chiu HF, Lee HH, Shen YC, Venkatakrishnan K, Wang CK. Consumption of onion juice modulates oxidative stress and attenuates the risk of bone disorders in middle-aged and post-menopausal healthy subjects. Food Funct. 2016 Feb;7(2):902-12.
16. doi: 10.1039/c5fo01251a. PMID: 26686359.
17. Li Q, Wang Y, Mai Y, Li H, Wang Z, Xu J, He X. Health Benefits of the Flavonoids from Onion: Constituents and Their Pronounced Antioxidant and Anti-neuroinflammatory Capacities. J Agric Food Chem. 2020 Jan 22;68(3):799-807. doi: 10.1021/acs.jafc.9b07418. Epub 2020 Jan 13. PMID: 31893634.
18. Tamtaji OR, Hosseinzadeh H, Talaei SA, Behnam M, Firoozeh SMT, Taghizadeh M, et al. Protective effects of red onion (Allium cepa) ethanolic extract on learning and memory impairments in animal models of diabetes. 2017;Galen Med J 6:249–57. doi:10.22037/ijpr.2020.112773.13940
19. Khan D, Mohammed M, Upaganlawar A, Upasani CD, Une HD. Ameliorative potential of Allium cepa Lam. leaves on diabetes induced and chronic constriction injury induced neuropathic pain in experimental rats. Indian J Pharm Educ Res. 2020;54:143–9. doi:10.5530/ijper.54.1.17
20. Kumar S, Modgil S, Bammidi S, Minhas G, Shri R, Kaushik S, Singh V, Anand A. Allium cepa exerts neuroprotective effect on retinal ganglion cells of pterygopalatine artery (PPA) ligated mice. J Ayurveda Integr Med. 2020 Oct-Dec;11(4):489-494. doi: 10.1016/j.jaim.2019.08.002. Epub 2020 Feb 20. PMID: 32088091; PMCID: PMC7772493.
21. Singh V, Shri R, Krishan P, Singh IP, Shah P. Isolation and characterization of components responsible for neuroprotective effects of Allium cepa outer scale extract against ischemia reperfusion induced cerebral injury in mice. J Food Sci. 2020 Nov;85(11):4009-4017. doi: 10.1111/1750-3841.15474. Epub 2020 Oct 14. PMID: 33051874.
22. Hyun SW, Jang M, Park SW, Kim EJ, Jung YS. Onion (Allium cepa) extract attenuates brain edema. Nutrition. 2013 Jan;29(1):244-9. doi: 10.1016/j.nut.2012.02.017. Epub 2012 Jul 6. PMID: 22771051.
23. Hegazy EM, Sabry A, Khalil WKB. Neuroprotective effects of onion and garlic root extracts against Alzheimer's disease in rats: antimicrobial, histopathological, and molecular studies. BioTechnologia (Pozn). 2022 Jun 29;103(2):153-167. doi: 10.5114/bta.2022.116210. PMID: 36606073; PMCID: PMC9642951.
24. Hwang IK, Lee CH, Yoo KY, Choi JH, Park OK, Lim SS, Kang IJ, Kwon DY, Park J, Yi JS, Bae YS, Won MH. Neuroprotective effects of onion extract and quercetin against ischemic neuronal damage in the gerbil hippocampus. J Med Food. 2009 Oct;12(5):990-5. doi: 10.1089/jmf.2008.1400. PMID: 19857061.
25. Bhanot A, Shri R. A comparative profile of methanol extracts of Allium cepa and Allium sativum in diabetic neuropathy in mice. Pharmacognosy Res. 2010 Nov;2(6):374-84. doi: 10.4103/0974-8490.75460. PMID: 21713142; PMCID: PMC3111698.