ISSN:2958-0420 Contents lists available at JJOAS-N

Jordan Journal of Applied Science - Natural Science Series
Applied Science Private University

Research Article *Vol. 19*

Protective Effects of Aloe vera Methanol Extract Against Ethanol-Induced Steatosis, Mitotic Arrest, and Oxidative Stress in Balb/c Mice.

Sunday Joseph Manye[1], Nathan Isaac Dibal[1*], Helga Bedan Ishaya[1], Martha Orendu Oche Attah[1,2], Samaila Musa Chiroma[1,3].

[1]Department of Human Anatomy, University of Maiduguri, Maiduguri, Nigeria.

[2]Faculty of Medicine, Cyprus International University, Nicosia, Cyprus.

[3]Anatomy Working Group, Newcastle University Medicine Malaysia, Johor, Malaysia.

ARTICLE INFO

Article history:

Received 7 Oct 2024

Accepted 29 Dec 2024

Published 13 Jan 2025

DOI: https://doi.org/10.35192/jjoas-n.v19i1.2024

***Corresponding author:**

Department of Human Anatomy, University of Maiduguri, Maiduguri, Nigeria

Email: nathandibal@unimaid.edu.ng

ABSTRACT

Background: *Aloe vera* has a wide range of traditional uses such as the treatment of wounds and infections, liver disease, and hypertension. The study evaluated the effect of methanol extract of *Aloe vera* (MEAL) on liver function, oxidative stress markers and liver histology in ethanol-treated mice.

Methods: Twenty-five mice were allotted into five groups (n=5). The mice received distilled water, 10 ml/kg of 20% ethanol, 50 mg/kg and 100 mg/kg MEAL plus 20% ethanol and 100 mg/kg silymarin plus 20% ethanol respectively for eighteen days. All the mice were euthanized thereafter and blood samples were collected in a plain bottle centrifuged and used to evaluate liver function markers while the liver was removed and processed for light microscopy. Oxidative stress markers were evaluated from the liver homogenate. The number of hepatocytes in the telophase stage of mitosis was counted.

Results: Ethanol treatment significantly elevated ($p< .05$) serum levels of AST and ALT relative to the control. However, pre-treatment with MEAL was shown to significantly reduce ($p< .05$) the AST and ALT levels compared to the ethanol treatment. The mice pre-treated with 50 mg/kg and 100 mg/kg MEAL displayed significantly higher ($p< .05$) catalase, SOD, and reduced glutathione activities relative to the ethanol-treated mice. Pre-treatment with MEAL prevents hepatocyte degeneration and steatosis as well as increases the number of cells at the telophase stage of mitosis.

Conclusion: Methanol extract of *Aloe vera* prevented hepatocyte distortion, and steatosis in ethanol-treated mice. It also regulates liver function, enhances antioxidant activity and promotes mitosis in liver cells.

Keywords: *Aloe vera,* Hepatocyte, Liver function, Mitosis, steatosis, Telophase.

Introduction

Alcohol consumption is a public health problem globally, it is a unique risk factor for several injuries and diseases including metabolic and mental disorders, as well as alcoholic liver disease (1,2). It contributes substantially to the overall global burden of diseases, including 5.3% of all deaths and 4–5% of all disability-adjusted life-years (DALYs) (2). Alcoholic liver disease (ALD) is a liver dysfunction that occurs as a result of alcohol consumption over a while (3). The spectrum begins with fatty liver which is characterized by hepatic steatosis (accumulation of triglycerides in hepatocytes). In most individuals, hepatic steatosis will progress to hepatic inflammation, injury and ballooning, which is histologically defined as alcoholic steatohepatitis (ASH). With continual alcohol consumption, ASH may progress to chronic liver injury, fibrosis, cirrhosis, and hepatocellular carcinoma (4). Previous studies suggest that about 90% of individuals who consume huge volumes of alcohol over time will develop fatty liver, while 25% and 15% will develop severe alcoholic hepatitis and liver cirrhosis respectively (3,5). Currently, ALD treatment can be achieved in two ways, depending on the stage of the disease. The first applies to the early stage of the disease and involves the discontinuation of alcohol with the introduction of food supplements (6). However, in the late stage of the disease (liver cirrhosis and/or hepatocellular carcinoma), a liver transplant is required (7).

Aloe vera (*Liliaceae* family) is a drought-resistant plant with a wide range of uses in both traditional and modern medicine (8). The term *Aloe vera* is coined from Arabic and Latin words meaning bitter and shiny in Arabic and truth in Latin (9). Previous studies reported that the different parts of *Aloe vera* have been used in the treatment of wounds (10), diabetes (11), several types of cancers

Published by Jordan Journal of Applied Science - Natural Science Series — This is an open access article under the CC BY 4.0 license.

(12), and liver disease (13). The biological activities of *Aloe vera* are attributed to the presence of Aloin A and B, emodin, phenols, acemannan, and flavonoids (14). In ancient Egypt, *Aloe vera* is known as a plant of immortality (15). In Indian and Bangladesh traditional medicine, it is used to treat sunburn, skin problems, wounds and infections (16). The Chinese use *Aloe vera* to treat diabetes, liver disease, and hypertension while the Ethiopians use the flower to treat stomach aches, liver problems, and infection (17). Aloe vera is listed in the Chinese and US pharmacopoeia as well as in the Thai herbal fundamental public health drug list for the treatment of wounds, diabetes, and liver disease (10). With the wide range of traditional medicinal uses of *Aloe vera* in different cultures, the current study will be a novel because it aims to evaluate the effect of methanol extract of *Aloe vera* on liver function, oxidative stress markers and liver histology in a mouse model of alcoholic liver disease. The methanol extract was used in the current study because our previous study reported that methanol extract of Aloe vera has higher phenol and tannin content as well as exhibiting a better free radical scavenging activities compared to the aqueous extract (18).

Materials and Methods

Drugs and chemicals

Ethanol and methanol (Poole, England) were used to induce liver damage and for the extraction of *Aloe vera* while Ketamine injection (Swiss Parental, India) was used as anaesthetics. All chemicals used were of analytical grade. The standard (silymarin) was purchased from a local pharmacy.

Plant authentication and extraction

Aloe vera was authenticated at the Faculty of Pharmacy Herbarium, University of Maiduguri, Nigeria (UMM/FPH/ASH/002). The whole plant was washed, homogenized using a blender and dissolved in Methanol (20g of Aloe vera in 20 litres of methanol) with constant shaking for 48 hours. The solutions were filtered and evaporated in an oven at 45 ° C to get the methanol extract (19).

Ethical approval

The research was approved by the Department of Human Anatomy Ethical Committee, University of Maiduguri (UM/HA/PGR18.19-09900). and conducted according to the National Institute of Health Guide for the Care and Use of Laboratory Animals and ARRIVE Guidelines. Dissection was performed under ketamine anesthesia and efforts were made to reduce suffering.

Experimental animals

Twenty-five (25) male Balb/c mice, 6-8 weeks old (18-24) g were used for the study. The animals were housed at the Department of Biochemistry Animal House, University of Maiduguri. They were fed with hybrid feed (Chikun Feed, Nigeria) and water *ad libitum* throughout the experiment.

Experiment design

The mice were allotted into five groups with five each. The mice received distilled water (normal control), 10 ml/kg of 20% ethanol (negative control), 50 mg/kg methanol extract of *Aloe vera* (MEAL) followed by 20% ethanol after 30 minutes, 100 mg/kg MEAL followed by 20% ethanol after 30 minutes, and 100 mg/kg silymarin followed by 20% ethanol after 30 minutes (positive control) respectively for eighteen days (20). The extract and ethanol were administered daily through oro-gastric intubation. All the mice were euthanized 24 hours after the last administration. The blood sample of each mouse was collected in a plain bottle while the liver was removed and divided into three parts. According to a previous study, nine days of mice's life is equivalent to one year of human life (21). Hence, we administered 20% ethanol to the mice for 18 days to mimic two years of continuous alcohol consumption in humans. Only male mice were used in the study because previous studies reported differing effects after alcohol consumption in male and female rodent (22,23)

Biochemical analysis

The blood was centrifuged at 5000 rpm and the serum levels of alanine aminotransferase (ALT), aspartate aminotransferase (AST), and albumin were determined spectrophotometrically using their respective kits (Randox Laboratories Ltd, US) according to the manufacturer's instructions.

Oxidative stress markers

One part of the liver was homogenized in normal saline and centrifuged at 5000 rpm. The supernatant was used to evaluate the activities of catalase, malondialdehyde (MDA), superoxide dismutase (SOD), and reduced glutathione as described in our previous study (20).

Histology and histochemical study

Part of the liver was fixed in neutral buffered formalin, dehydrated in graded alcohol, embedded in paraffin, and sectioned at 5 µm. The sections were cleared in xylene, rehydrated in graded alcohol, stained with hematoxylin and eosin (H&E), and mounted on glass slides. Another part of the liver was frozen, sectioned with a cryostat, stained with oil red O, and mounted on glass slides (20). The tissues (10 slides per group for H&E stain and 5 slides per group for oil red O stain) were interpreted by two researchers that are blinded to the groupings. Photomicrographs were taken with a microscope camera (M500, Version 3.7) at x200 and x400 magnification. Steatosis was confirmed with the presence of numerous hepatic vacuoles in H&E-stained tissues and fat droplets in oil-red O-stain tissues.

Mitotic division

To evaluate if ethanol and MEAL will affect mitosis, the number of hepatocytes in the telophase stage of mitosis was counted in 10 different fields of the liver (3 slides per group) at x400 magnification. A hepatocyte is considered to be at the telophase stage of mitosis when a single hepatocyte has two nuclei that are either completely separated or in the process of separation.

Statistical analysis

The data were analyzed with GraphPad Prism 9.0 (San Diego, USA). One-way analysis of variance followed by Sidak post-hoc test was carried out. Statistical significance was considered at $p < .05$ and results were presented as mean ± SE.

Results

Liver function

The liver function test (AST, ALT, and Albumin) was conducted to ascertain the role of MEAL in ethanol-treated mice. Treatment with 20% ethanol was shown to significantly elevate (p< .05) the serum levels of AST (38.40±1.50) and ALT (31.40±1.50) relative to the control. However, pre-treatment with MEAL at both 50 mg/kg and 100 mg/kg as well as silymarin was shown to significantly reduce (p< .05) the serum AST (28.00±1.64, 15.00±0.84, & 6.84±0.34 respectively) and ALT (23.80±1.50, 20.80±1.20, & 26.00±1.67 respectively) compared to the ethanol-treated mice (Figure 1). The serum ALT level was normalized in mice pre-treated with 100 mg/kg MEAL to a level comparable to that of the control (9.00±0.84) at p> .05. Ethanol treatment was found to decrease serum albumin (1.71±0.15) level significantly (p< .05) relative to the MEAL pre-treated mice and the control (3.64±0.11). Moreover, pre-treatment with MEAL (2.42±0.16 & 2.98±0.12) and silymarin (4.18±0.09) was able to elevate the albumin level significantly compared to the ethanol-treated mice, Figure 1.

Oxidative stress markers

The oxidative stress marker was evaluated to identify the antioxidant effect of MEAL in ethanol-treated mice. The result showed a significant reduction (p< .05), in catalase (1.82±0.31), SOD (4.10±0.44) and reduced glutathione activities (26.44±0.87) in ethanol-treated mice compared to the control (7.54±0.39, 11.00±0.63, & 70.48±3.60). The mice that were pre-treated with MEAL displayed significantly higher (p< .05) catalase (5.08±0.56 & 4.62±0.36), SOD (8.50±0.59 & 7.40±0.12) and reduced glutathione (42.70±1.81 & 44.56±3.45) activities relative to the mice that receive only ethanol. Pretreatment with silymarin also significantly enhanced (p< .05) catalase (7.84±0.48) and SOD (10.70±0.15) activities compared to the ethanol-treated mice (Figure 2). Lipid peroxidation was significantly high (p< .05) in ethanol-treated mice (247.6±12.50) compared to the control (88.70±5.27). However, a significant reduction (p< .05) in lipid peroxidation was observed in the mice that were pre-treated with MEAL (142.5±13.28 & 106.70±5.43) and silymarin (77.7±0.86); with a value close to that of the control, Figure 3.

Histology and histochemical study

The histological and histochemical studies were carried out to evaluate the effect of MEAL on the hepatocytes and fat accumulation in the liver. The liver photomicrograph of the control and the mice pre-treated with 100 mg/kg MEAL and silymarin showed normal hepatocytes with numerous cells at the telophase stage of mitosis (Figures 4a, 4d, 4e, 5a, 5d & 5e). The liver tissue of mice that received 20% ethanol revealed distorted hepatocytes with numerous vacuoles within and few cells at the telophase stage of mitosis (Figures 4b & 5b). The liver tissue of mice pre-treated with 50 mg/kg MEAL showed distorted hepatocytes with little or no vacuoles and a moderate number of cells at the telophase stage of mitosis (Figures 4c & 5c). The liver tissue of the control and mice pre-treated with 100 mg/kg MEAL and silymarin showed negative staining for oil red O indicative of little or no fat accumulation (Figures 6a, 6d & 6e). The liver of mice that received 20% ethanol and the mice that were pre-treated with 50 mg/kg MEAL revealed positive staining for oil red O indicating fat accumulation (steatosis). However, the ethanol-treated mice liver showed a high density of fat stains compared to the mice pre-treated with 50 mg/kg MEAL which indicates low-density staining (Figures 6b & 6c).

Mitotic division

This study was done to ascertain the role of MEAL on mitosis using the telophase stage as an indication. The result revealed significantly lower (p< .05) hepatocytes at the telophase stage in ethanol-treated mice (5.90±0.38) compared to the control (13.30±0.73). Pre-treatment with MEAL (9.80±0.42 & 11.70±0.47) and silymarin (14.04±0.33) was shown to significantly elevate (p< .05) the hepatocytes at the telophase stage compared to that of ethanol-treated mice (5.90±0.38). The hepatocyte numbers of the mice pre-treatment with 100 mg/kg of MEAL (11.70±0.47) and silymarin (14.04±0.33) were comparable to those of the control (13.30±0.73) (Figure 7).

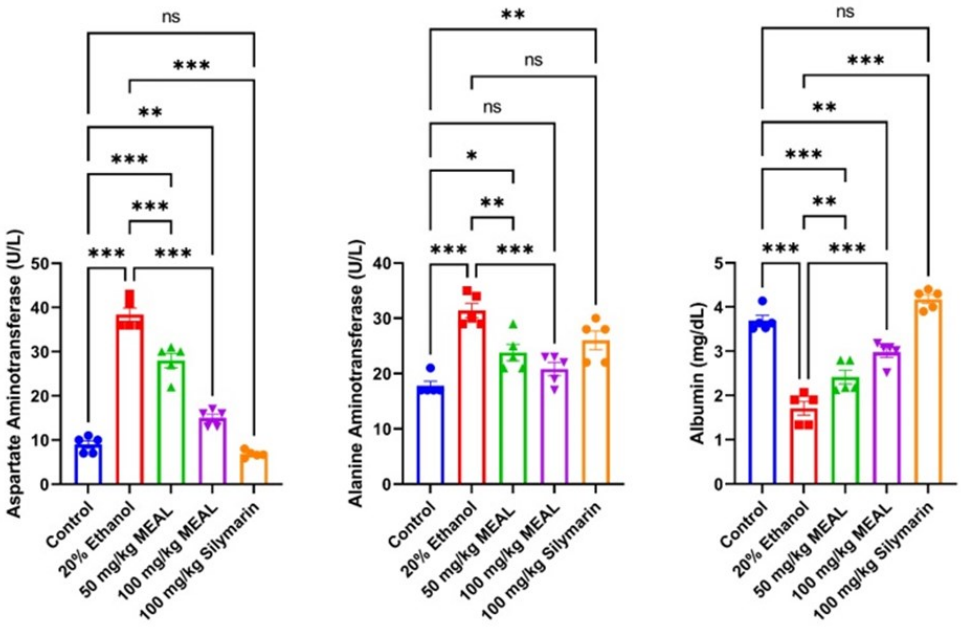

Figure 1. Liver function of ethanol-treated mice pretreated with MEAL. *, **, & *** indicate statistical significance at p= .011, .009 & <.001 respectively. MEAL= methanol extract of Aloe vera while ns= no significant change.

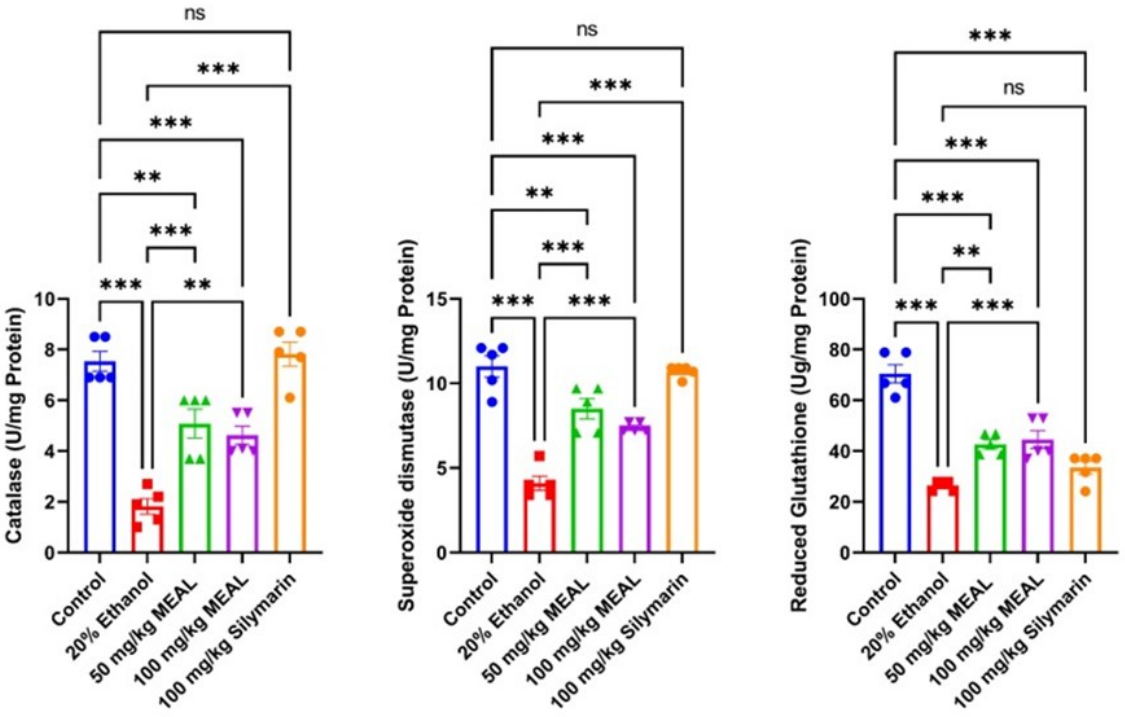

Figure 2. The antioxidant status of ethanol-treated mice pretreated with MEAL. *, **, & *** indicate statistical significance at p= .011, .009 & <.001 respectively. MEAL= methanol extract of Aloe vera while ns= no significant change.

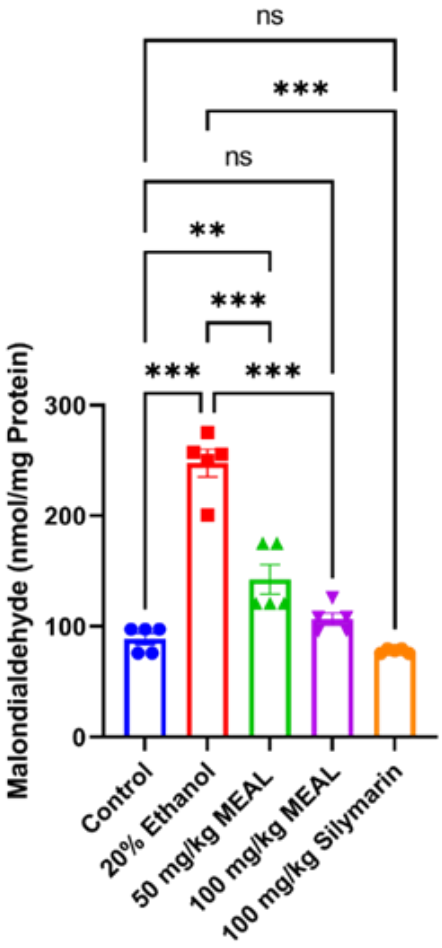

Figure 3. Malondialdehyde level of ethanol-treated mice pretreated with MEAL. *, **, & *** indicate statistical significance at p= .011, .009 & <.001 respectively. MEAL= methanol extract of Aloe vera while ns= no significant change.

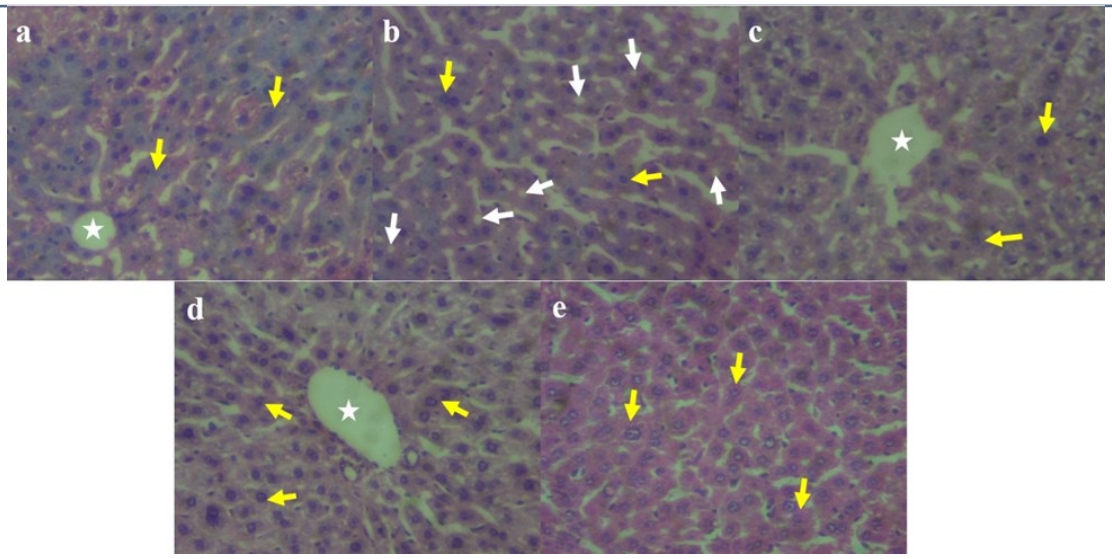

Figure 4. Liver photomicrograph of ethanol-treated mice pretreated with MEAL showing central vein (white star), hepatocytes (yellow arrows), and vacuoles (white arrows). MEAL= methanol extract of Aloe vera, a= control, b= 20% ethanol, c= 50 mg/kg MEAL plus 20% ethanol, d= 100 mg/kg MEAL plus 20% ethanol, e= 100 mg/kg Silymarin plus 20% ethanol, H&E stain x200 magnification.

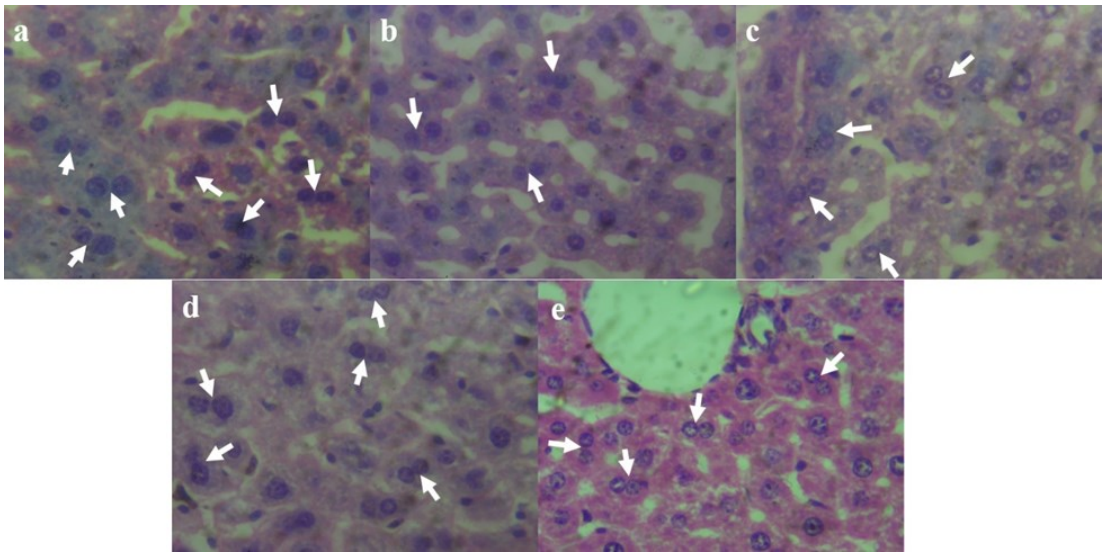

Figure 5. Liver photomicrograph of ethanol-treated mice pretreated with MEAL showing hepatocytes at the telophase stage of mitosis (white arrows). MEAL= methanol extract of Aloe vera, a= control, b= 20% ethanol, c= 50 mg/kg MEAL plus 20% ethanol, d= 100 mg/kg MEAL plus 20% ethanol, e= 100 mg/kg Silymarin plus 20% ethanol, H&E stain x400 magnification.

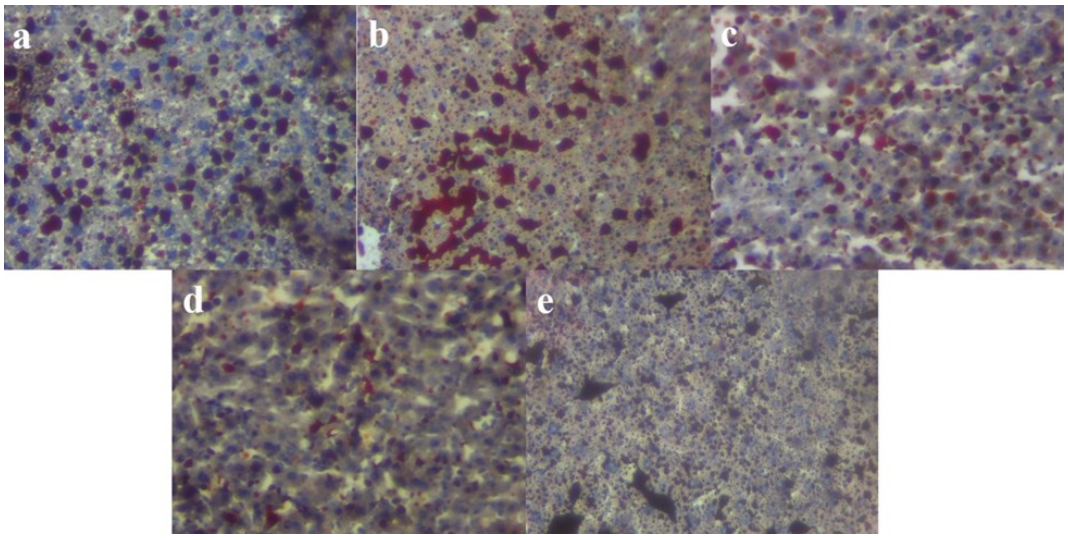

Figure 6. Liver photomicrograph of ethanol-treated mice pretreated with MEAL showing a negative fat staining in A & D, positive dense fat staining in B and a positive less dense fat staining in C. MEAL= methanol extract of Aloe vera, a= control, b= 20% ethanol, c= 50 mg/kg MEAL plus 20% ethanol, d= 100 mg/kg MEAL plus 20% ethanol, e= 100 mg/kg Silymarin plus 20% ethanol, oil red O stain x200 magnification.

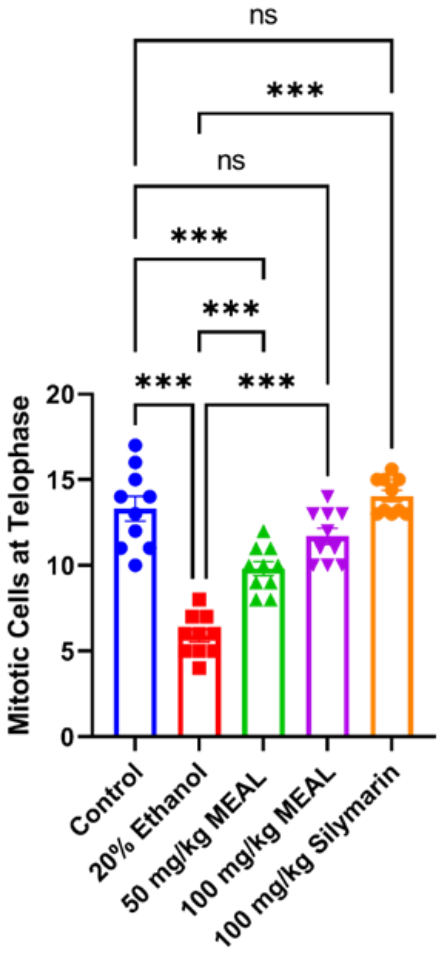

Figure 7. The number of mitotic cells at telophase of ethanol-treated mice pretreated with MEAL. *, **, & *** indicate statistical significance at p= .011, .009 & <.001 respectively. MEAL= methanol extract of Aloe vera while ns= no significant change.

Discussion

Our study demonstrated that the methanol extract of *Aloe vera* prevented hepatocyte distortion, and steatosis in ethanol-treated mice. It also regulates liver function, enhances antioxidant activity and promotes mitosis in liver cells. This suggests that *Aloe vera* could serve as a natural remedy for alcoholic liver disease and in the promotion of liver regeneration.

The result of the current study revealed an improved liver function i.e., a significant decrease in AST and ALT in MEAL pre-treated mice compared to the ethanol-treated. Previous reports established an association between elevated AST and ALT levels with hepato-biliary disease, viral hepatitis and alcohol consumption (24-26). The increase in serum AST and ALT coupled with distorted hepatocytes and vacuoles within the liver tissue that was observed among ethanol-treated mice in the present study is an indication that could cause liver injury and inflammation. A previous report proposes that nine days of mice's life is equivalent to one year of human life (18). In our study, we administered 20% alcohol to mice for 18 days which mimics two years of continuous alcohol consumption in humans to evaluate the effect of alcohol and the possible role of *Aloe vera*. From the result, we hypothesized that the decreased serum level of AST and ALT and the normal liver histology that was observed in MEAL pre-treated mice is because MEAL prevented hepatocyte degeneration and liver injury caused by alcohol. Albumin level was significantly decreased in ethanol-treated mice in the current study. Albumin is a plasma protein produced by the hepatocytes and responsible for transporting both endogenous and exogenous compounds. An increased level of albumin was reported to reduce mortality in patients with liver cirrhosis suggesting that a high albumin level is good (27,28). We suggested that the possible mechanism through which MEAL increases albumin level in the present study is as follows; the albumin is coupled with and transports alcohol (exogenous compound) thereby preventing its contact breakdown by the liver cells as. Hence, preventing liver injury and promoting more albumin production. These was similar to what was reported in previous studies that albumin level could be used to predict chronic liver disease (29,30).

In the current study, MEAL was able to enhance antioxidant activities by elevating catalase, SOD, and reduced glutathione levels. A previous study reported an increase in catalase and glutathione levels following dietary supplementation with *Aloe vera* (31). Another study reported a boost in the antioxidant activities of *Aloe vera* in mice exposed to X-ray and preventing hepatic and renal damage caused by the X-ray (32). Aloe vera was also reported to improve the antioxidant status of streptozotocin-induced diabetic rats (33). We postulated that MEAL improves antioxidant activity by scavenging free radicals and preventing lipid peroxidation.

The oil red O staining was conducted to determine whether the vacuoles found in the liver of ethanol-treated mice were triglycerides (fat cells). The result revealed that ethanol treatment causes steatosis (fatty liver) as indicated by the positive high-density fat stain. However, pre-treatment with MEAL was shown to prevent

steatosis. Previous studies have shown that *Aloe vera* has hepatoprotective properties by preventing liver damage and non-alcoholic steatohepatitis in rodents (34,35). We hypothesized that MEAL prevents steatosis by enhancing emulsification, digestion and absorption of fat. The reduced number of hepatocytes at the telophase stage of mitosis in ethanol-treated mice is an indication that ethanol consumption could affect liver cell regeneration. The liver can regenerate from several types of injuries. In severe liver injury with hepatocyte proliferation, liver stem cells differentiate into hepatocytes and biliary epithelial cells. These cells multiply and contribute to regeneration (36). Pre-treatment with MEAL promoted liver cell differentiation suggesting that MEAL is capable of replenishing damaged cells by triggering mitosis and liver cell regeneration. The protective effect of MEAL that was observed in the present study might be due to the presence of flavonoids, phenols and tannins that was reported in a previous study (18).

Limitations of the Study and Recommendations for Future Work

The present study is limited to evaluating the effect of MEAL on liver function, oxidative stress markers and liver histology in mice that received alcohol for eighteen days (acute alcohol consumption). Therefore, the result of the present study may not be applicable in chronic alcohol consumption as well as studies involving different animal models. We recommend further studies with chronic alcohol consumption and with different animal models exploring inflammatory markers and the genes associated with liver diseases.

Conclusion

Conclusively, our findings revealed that MEAL could regulate liver function, promote antioxidant activity and prevent steatosis in ethanol-treated mice. It also promoted mitosis in liver cells. This suggests that MEAL could prevent liver injury and can be used as a nutrient supplement for treating early-stage alcoholic liver disease after alcohol withdrawal.

Declaration of Interests

The authors declare that they have no competing interests.

Data Sharing

The dataset used in the study is available from the corresponding author on request.

Funding

None

Author Contributions

Concept and design: All authors. Data Collection and Processing: All authors. Analysis, and Interpretation: NID, HBI, & MOOA. Literature search: SJM, NID, & SMC. Writing: SJM, NID, & HBI. Review: MOOA & SMC.

References

1. Burton R, Sheron N. No level of alcohol consumption improves health. Lancet. 2018;392(10152):987-988. doi:10.1016/S0140-6736(18)31571-X.

2. World Health Organization. Global status report on alcohol and health 2018. Geneva: World Health Organization; 2018. ISBN: 9789241565639. Available from: https://www.who.int/publications/i/item/9789241565639

3. Kong LZ, Chandimali N, Han YH, Lee DH, Kim JS, Kim SU, et al. Pathogenesis, early diagnosis, and therapeutic management of alcoholic liver disease. Int J Mol Sci. 2019;20(11):2712. doi:10.3390/ijms20112712.

4. Seitz HK, Bataller R, Cortez-Pinto H, Gao B, Gual A, Lackner C, et al. Alcoholic liver disease. Nat Rev Dis Primers. 2018;4:16. doi:10.1038/s41572-018-0014-7.

5. Tan Z, Sun H, Xue T, Gan C, Liu H, Xie Y, et al. Liver fibrosis: therapeutic targets and advances in drug therapy. Front Cell Dev Biol. 2021;9:730176. doi:10.3389/fcell.2021.730176.

6. Suk KT, Kim MY, Baik SK. Alcoholic liver disease: treatment. World J Gastroenterol. 2014;20(36):12934-12944. doi:10.3748/wjg.v20.i36.12934.

7. Stickel F, Datz C, Hampe J, Bataller R. Pathophysiology and management of alcoholic liver disease: update 2016. Gut Liver. 2017;11(2):173-188. doi:10.5009/gnl16477.

8. Gamboa-Gómez CI, Rocha-Guzmán NE, Gallegos-Infante JA, Moreno-Jiménez MR, Vázquez-Cabral BD, González-Laredo RF. Plants with potential use on obesity and its complications. EXCLI J. 2015;14:809-831. doi:10.17179/excli2015-186.

9. Guo X, Mei N. Aloe vera: a review of toxicity and adverse clinical effects. J Environ Sci Health C Environ Carcinog Ecotoxicol Rev. 2016;34(2):77-96. doi:10.1080/10590501.2016.1166826.

10. Razia S, Park H, Shin E, Shim KS, Cho E, Kang MC, et al. Synergistic effect of Aloe vera flower and Aloe gel on cutaneous wound healing targeting MFAP4 and its associated signaling pathway: in-vitro study. J Ethnopharmacol. 2022;290:115096. doi:10.1016/j.jep.2022.115096.

11. Muñiz-Ramirez A, Perez RM, Garcia E, Garcia FE. Antidiabetic activity of Aloe vera leaves. Evid Based Complement Alternat Med. 2020;2020:6371201. doi:10.1155/2020/6371201.

12. Majumder R, Das CK, Mandal M. Lead bioactive compounds of Aloe vera as potential anticancer agent. Pharmacol Res. 2019;148:104416. doi:10.1016/j.phrs.2019.104416.

13. Dibal NI, Buba F, Chiroma SM, Goni ZM, Kilobas HE, Sheriff H, et al. Aloe vera ameliorates hyperlipidemia, enhances endogenous antioxidant activity and regulates liver function in high fat diet fed mice. Mediterr J Nutr Metab. 2022;15(4):505-515. doi:10.3233/MNM-220028.

14. Leiva-Cala C, Lorenzo-Pouso AI, Centenera-Centenera B, López-Palafox J, Gándara-Vila P, García-García A, et al. Clinical efficacy of an Aloe Vera gel versus a 0.12% chlorhexidine gel in preventing traumatic ulcers in patients with fixed orthodontic appliances: a double-blind randomized clinical trial. Odontology. 2020;108(3):470-478. doi:10.1007/s10266-019-00468-w.

15. Anand U, Tudu CK, Nandy S, Sunita K, Tripathi V, Loake GJ, et al. Ethnodermatological use of medicinal plants in India: from ayurvedic formulations to clinical perspectives—a review. J Ethnopharmacol. 2022;284:114744. doi:10.1016/j.jep.2021.114744.

16. Saleem A, Naureen I, Naeem M, Murad HS, Maqsood S, Tasleem G. Aloe vera gel effect on skin and pharmacological properties. Sch Int J Anat Physiol. 2022;5(1):1-8. doi:10.36348/sijap.2022.v05i01.001.

17. Belayneh A, Demissew S, Bussa NF, Bisrat D. Ethno-medicinal and bio-cultural importance of aloes from south and east of the Great Rift Valley floristic regions of Ethiopia. Heliyon. 2020;6(6):e04344. doi:10.1016/j.heliyon.2020.e04344.

18. Manye SJ, Saleh JS, Ishaya HB, Chiroma SM, Attah MOO, Dibal NI. Phytochemical screening and in-vitro antioxidant activities of aqueous and methanol extracts of Aloe vera. Pharmacol Res Mod Chin Med. 2023;8:100291. doi:10.1016/j.prmcm.2023.100291.

19. Bahrin N, Muhammad N, Abdullah N, Talip BHA, Jusoh S, Theng SW. Effect of processing temperature on antioxidant activity of Ficus carica leaves extract. J Sci Technol. 2018;10(2):99-103. doi:10.30880/jst.2018.10.02.016.

20. Dibal NI, Garba SH, Jacks TW. Onion peel quercetin attenuates ethanol-induced liver injury in mice by preventing oxidative stress and steatosis. Biomed Res Ther. 2022;9(6):5102-5112. doi:10.15419/bmrat.v9i6.745.

21. Dutta S, Sengupta P. Men and mice: relating their ages. Life Sci. 2016;152:244-248. doi:10.1016/j.lfs.2015.10.025.

22. Li J, Chen P, Han X, Zuo W, Mei Q, Bian EY, et al. Differences between male and female rats in alcohol drinking, negative affects and neuronal activity after acute and prolonged abstinence. Int J Physiol Pathophysiol Pharmacol. 2019;11(4):163-176. PMID:31523363. Available from: https://pubmed.ncbi.nlm.nih.gov/31523363/

23. Mittal N, Fleming SM, Martinez A, Thakore N, Bell RL, Maddox WT, et al. Sex differences in cognitive performance and alcohol consumption in high alcohol-drinking (HAD-1) rats. Behav Brain Res. 2020;381:112456. doi:10.1016/j.bbr.2019.112456.

24. Loh KY, Tong KS. Elevated ALT and AST in an asymptomatic person: what the primary care doctor should do? Malays Fam Physician. 2009;4(2-3):98-99. PMID:25606173. Available from: https://pubmed.ncbi.nlm.nih.gov/25606173/

25. Darvishi-Khezri H, Karami H, Naderisorki M, Zahedi M, Razavi A, Kosaryan M, et al. Moderate to severe liver siderosis and raised AST are independent risk factors for vitamin D insufficiency in β-thalassemia patients. Sci Rep. 2020;10(1):21164. doi:10.1038/s41598-020-78230-4.

26. Metra BM, Guglielmo FF, Halegoua-DeMarzio DL, Civan JM, Mitchell DG. Beyond the liver function tests: a radiologist's guide to the liver blood tests. Radiographics. 2022;42(1):125-142. doi:10.1148/rg.210137.

27. Tufoni M, Zaccherini G, Caraceni P, Bernardi M. Albumin: indications in chronic liver disease. United European Gastroenterol J. 2020;8(5):528-535. doi:10.1177/2050640620910339.

28. Paar M, Fengler VH, Rosenberg DJ, Krebs A, Stauber RE, Oettl K, et al. Albumin in patients with liver disease shows an altered conformation. Commun Biol. 2021;4(1):731. doi:10.1038/s42003-021-02269-w.

29. Jagdish RK, Maras JS, Sarin SK. Albumin in advanced liver diseases: the good and bad of a drug! Hepatology. 2021;74(5):2848-2862. doi:10.1002/hep.31836.

30. Amri A, Bouraoui Z, Balbuena-Pecino S, Capilla E, Gharred T, Haouas Z, et al. Dietary supplementation with Aloe vera induces hepatic steatosis and oxidative stress together with a disruption of cellular signaling pathways and lipid metabolism related genes' expression in gilthead sea bream (Sparus aurata). Aquaculture. 2022;559:738433. doi:10.1016/j.aquaculture.2022.738433.

31. Bala S, Chugh NA, Bansal SC, Garg ML, Koul A. Radiomodulatory effects of Aloe vera on hepatic and renal tissues of X-ray irradiated mice. Mutat Res Fundam Mol Mech Mutagen. 2018;811:1-15. doi:10.1016/j.mrfmmm.2018.07.001.

32. Tabatabaei SRF, Ghaderi S, Bahrami-Tapehebur M, Farbood Y, Rashno M. Aloe vera gel improves behavioral deficits and oxidative status in streptozotocin-induced diabetic rats. Biomed Pharmacother. 2017;96:279-290. doi:10.1016/j.biopha.2017.09.146.

33. Sehitoglu MH, Karaboga I, Kiraz A, Kiraz HA. The hepatoprotective effect of Aloe vera on ischemia-reperfusion injury in rats. North Clin Istanb. 2019;6(3):203-209. doi:10.14744/nci.2018.82957.

34. Klaikeaw N, Wongphoom J, Werawatganon D, Chayanupatkul M, Siriviriyakul P. Anti-inflammatory and anti-oxidant effects of aloe vera in rats with non-alcoholic steatohepatitis. World J Hepatol. 2020;12(7):363-377. doi:10.4254/wjh.v12.i7.363.

35. Miyaoka Y, Miyajima A. To divide or not to divide: revisiting liver regeneration. Cell Div. 2013;8(1):8. doi:10.1186/1747-1028-8-8.